

심폐재활

게시일시 및 장소 : 10 월 19 일(토) 08:30-12:30 Room G(3F)

질의응답 일시 및 장소 : 10 월 19 일(토) 11:00-11:30 Room G(3F)

P 3-116

## A Uncommon Complication of Edoxaban, Non-Traumatic Quadriceps Hematoma

Beom Suk Kim, M.D.<sup>1\*</sup>, Jeongmin Kim<sup>1</sup>, Joon Shik Yoon, M.D., Ph.D.<sup>1†</sup>

Korea University Guro Hospital, Department of Rehabilitation Medicine<sup>1</sup>

Poster

**KU MEDICINE** A Uncommon Complication of Edoxaban, Non-Traumatic Quadriceps Hematoma  
Beomsuk Kim, M.D., Joonshik Yoon, M.D., Ph.D.  
Department of Physical Medicine and Rehabilitation, Korea University College of Medicine

### CASE REPORT

INTRODUCTION	MRI FINDINGS
<ul style="list-style-type: none"><li>● <b>Edoxaban</b>, an oral anticoagulant drug acting as a <i>direct factor Xa inhibitor</i>, is commonly used for prevention of stroke and thromboembolism in patients with <i>nonvalvular atrial fibrillation</i>.</li><li>● We report a uncommon case of <b>Non-traumatic quadriceps hematoma</b> presenting as a <b>uncommon complication of edoxaban</b>.</li></ul>	<ul style="list-style-type: none"><li>● MRI showed 9.3 x 5.6 x 2.1 cm – sized multilobulated mass-like lesion in inter- and intra-muscular layer mainly involving <b>proximal vastus lateralis and intermedius</b> of the right thigh.</li><li>● The lesion showed heterogenous T1, T2 high signal portion and T2 low signal portion, suggesting variable stage hematoma torus lesion.</li></ul>

### CASE PRESENTATION

● A 69-year-old female presented with acute onset of **bruise and pain in the right thigh**.

● She had been taking **edoxaban** for the past year after newly diagnosed *nonvalvular atrial fibrillation*.

● Other medical conditions included hypertension and she took breast cancer surgery 15 months ago.

● She gave **no history of direct trauma or excessive sports activity**.

### PHYSICAL EXAMINATION

● On inspection, an **extensive bruise** was found on the **anteromedial side of the right thigh** (Figure 1).

● Motor and sensory examinations showed normal findings.

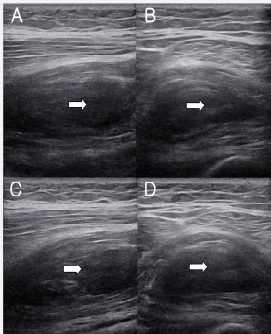
Table 1. The circumferences of the thigh at initial visit.

	Right (cm)	Left (cm)	Difference (cm)
Upper 1/3	48.5	42.5	6
Lower 1/3	41	37	4

Figure 1. Suspected hematoma of the right thigh.

### ULTRASONOGRAPHIC FINDINGS

● Ultrasonography showed heterogenous and mixed-echogenic lesion **extensively** located in **lateral and intermedius vastus muscles** (Figure 2).



### TREATMENT

- On the initial visit, we referred her to the cardiology department for further evaluation and treatment.
- After cardiologic consultation, **edoxaban medication was held** and she decided to receive **radiofrequency catheter ablation**.
- We instructed her to wear **compression stocking** for **reducing edema and promoting hematoma resolution**.
- She was also instructed to **avoid excessive sports activity** which could worsen the symptoms.
- **Acetaminophen** was prescribed and **cold pack** was applied for **pain control**.
- **A month** after the initial visit, **bruise and pain** of the right thigh were **significantly improved**.
- The thigh circumferences were also reduced to be comparable to the uninvolved side (Table 2).

Figure 3. MRI findings showing large hematoma (white arrow) of right vastus lateralis and intermedius muscles.

Inter- and intra-muscular large hematoma of proximal vastus lateralis and intermedius, right.

Table 2. The circumferences of the thigh at 1-month follow-up.

	Right (cm)	Left (cm)	Difference (cm)
Upper 1/3	42.9	42.5	0.4
Lower 1/3	38	37	1

### DISCUSSION

- **Non-traumatic quadriceps hematoma** can be manifested as a **uncommon complication of edoxaban medication**.
- **Ultrasound and MRI** are **effective diagnostic tools** for detecting inter- and intra-muscular hematoma.

